

AGE

42

## DCIS BREAST CASE STUDY

PATIENT	42 Year-Old Female Patient
TUMOR SIZE (cm)	1.5
MENOPAUSAL STATUS	Pre-Menopausal
ER STATUS (IHC)	ER positive
MULTIFOCAL	N/A
MARGIN WIDTH (mm)	N/A
NUCLEAR GRADE	N/A
COMEDO NECROSIS	N/A
GENERAL HEALTH	N/A
OTHER INFORMATION	Patient was considering no surgery because of low grade, and had also indicated she was not interested in radiation. However, when she received her DCIS Score, she decided on lumpectomy and whole-breast radiation and is considering tamoxifen.
SUBMITTED BY	Michael Alvarado, MD, University of California, San Francisco, CA

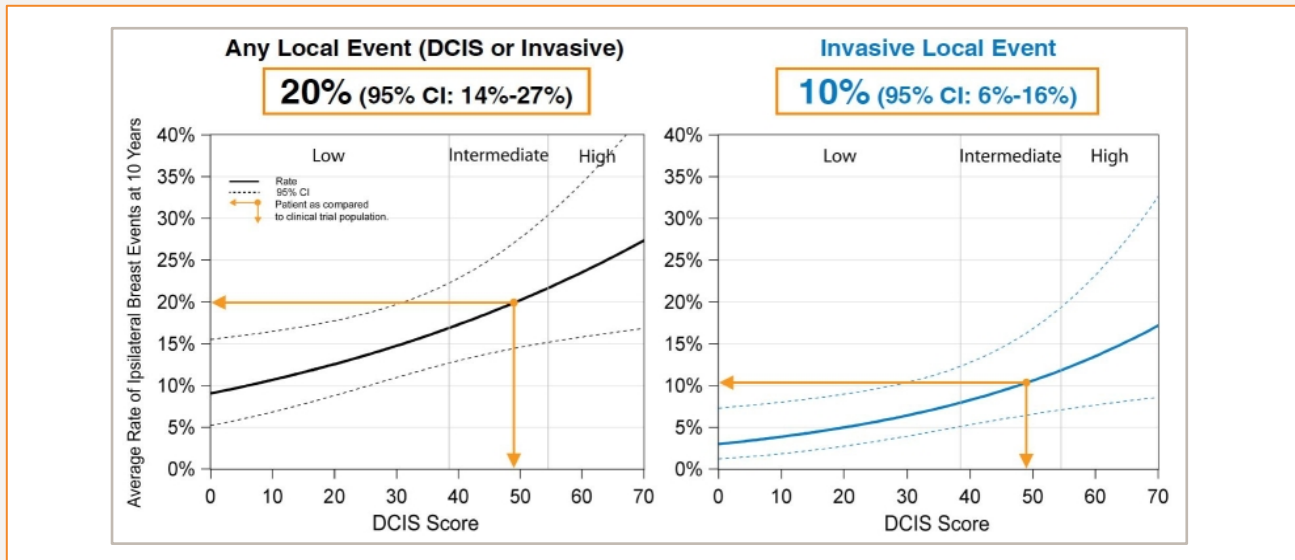
DCIS SCORE™

49

# DCIS BREAST CASE STUDY

## QUANTITATIVE HORMONE RECEPTOR

The Clinical Validation study<sup>1</sup> included female patients with DCIS treated with local excision without irradiation, and required clear surgical margins  $\geq 3$  mm and a lesion size of  $\leq 2.5$  cm. Approximately a third of patients were treated with tamoxifen. The average 10 year rate for ipsilateral breast events for patients who had a DCIS Score of 49 was:



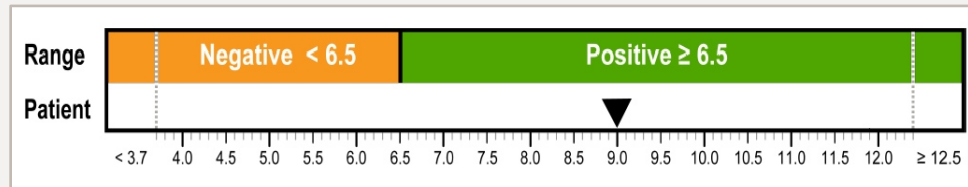
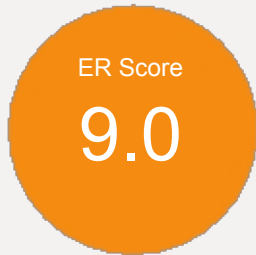TREATMENT GIVEN

N/A

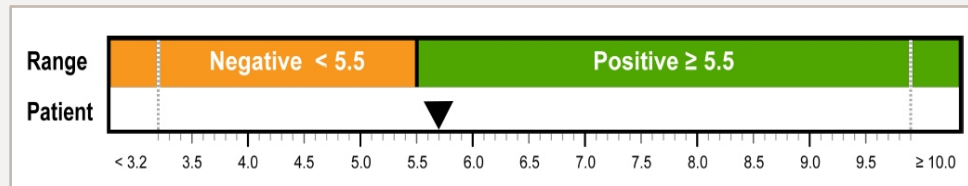
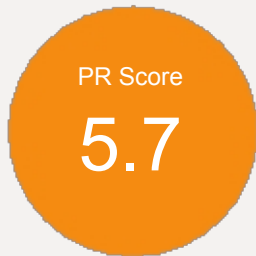# DCIS BREAST CASE STUDY

## CLINICAL INFORMATION

The Oncotype DX test uses RT-PCR to determine the RNA expression of the genes below. These results may differ from ER or PR results reported using other methods or reported by other laboratories.



N/A



N/A

### References

1. Solin et al. J Natl Cancer Inst. 2013.
2. ER Score based on quantitative ESR1 expression (estrogen receptor); PR Score based on quantitative PGR expression (progesterone receptor).
3. Badve et al. J Clin Oncol. 2008. May 20;25(15):2473-81
4. Paik et al. ASCO 2005.