

Colon Case Study

oncotype DX[®]
Colon Cancer Assay

65-Year-Old Male Patient

Tumor Type: Adenocarcinoma

Tumor Stage: Stage III A/B (N1-3)

Histologic Grade: Low (1)

Lymph Node Status: Positive

Number of Lymph Nodes Assessed: 15

Mismatch Repair (MMR) Status: MMR-P (MSS)

Lymphovascular Invasion: Absent

Perforation: Absent

Obstruction: Absent

Other Information: Patient has hypertension, diabetes, high cholesterol, acid reflux, and sleep apnea.

Treatment: Capecitabine and Oxaliplatin

CASE SUBMITTED BY:

Putao Cen, MD
University of Texas
Houston, TX

Colon Case Study

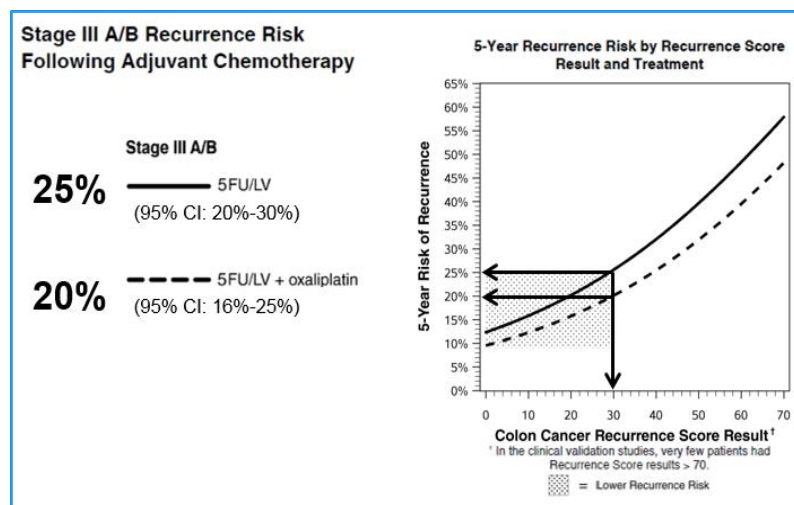
CLINICAL EXPERIENCE

Recurrence Score = **30**

Prognosis for Stage III A/B Colon Cancer Patients Following Adjuvant Chemotherapy

The clinical validation study included patients from the NSAPB C-07 trial which randomized 409 stage III A/B patients to 5FU/LV versus 5FU/LV+oxaliplatin.¹

The average 5 year risk of recurrence for patients who had a Recurrence Score[®] result of 30 was:



Other Considerations: The recurrence risk for patients with ≥ 12 nodes examined was lower than the risk for those with < 12 nodes examined.

References:

1. Yothers et al. J Clin Oncol. 2013.