

# Colon Case Study

oncotype DX<sup>®</sup>  
*Colon Cancer Assay*

## 65-Year-Old Male Patient

**Tumor Type:** Adenocarcinoma

**Tumor Stage:** Stage III A/B (N1-3)

**Histologic Grade:** Low (1)

**Lymph Node Status:** Positive

**Number of Lymph Nodes Assessed:** 92

**Mismatch Repair (MMR) Status:** MMR-P (MSS)

**Lymphovascular Invasion:** Present

**Perforation:** Present

**Obstruction:** Present

**Other Information:** Patient has hypertension and diabetes

Treatment: FOLFOX

### CASE SUBMITTED BY:

Putao Cen, MD

University of Texas

Houston, TX

# Colon Case Study

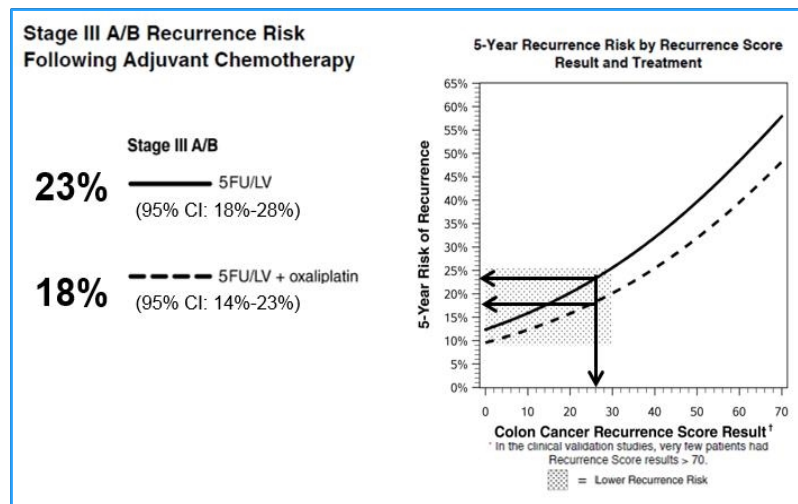
## CLINICAL EXPERIENCE

Recurrence Score = **26**

### Prognosis for Stage III A/B Colon Cancer Patients Following Adjuvant Chemotherapy

The clinical validation study included patients from the NSAPB C-07 trial which randomized 409 stage III A/B patients to 5FU/LV versus 5FU/LV+oxaliplatin.<sup>1</sup>

The average 5 year risk of recurrence for patients who had a Recurrence Score<sup>®</sup> result of 26 was:



Other Considerations: The recurrence risk for patients with  $\geq 12$  nodes examined was lower than the risk for those with  $< 12$  nodes examined.

#### References:

1. Yothers et al. J Clin Oncol. 2013.