

AGE

78

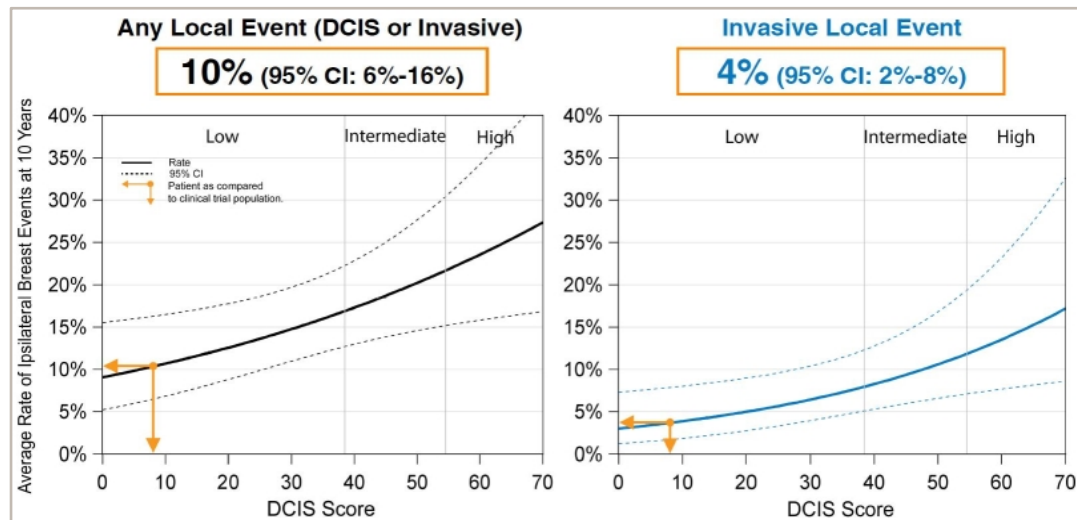
DCIS BREAST CASE STUDY

PATIENT	78 Year-Old Female Patient
TUMOR SIZE (cm)	1.0
MENOPAUSAL STATUS	Post-Menopausal
ER STATUS (IHC)	ER positive
MULTIFOCAL	N/A
MARGIN WIDTH (mm)	5
NUCLEAR GRADE	N/A
COMEDO NECROSIS	N/A
GENERAL HEALTH	Good
OTHER INFORMATION	N/A
SUBMITTED BY	Elisabeth Dupont, MD, Watson Clinic LLP, Lakeland, Florida

DCIS BREAST CASE STUDY

QUANTITATIVE HORMONE RECEPTOR

The Clinical Validation study¹ included female patients with DCIS treated with local excision without irradiation, and required clear surgical margins ≥ 3 mm and a lesion size of ≤ 2.5 cm. Approximately a third of patients were treated with tamoxifen. The average 10 year rate for ipsilateral breast events for patients who had a DCIS Score of 8 was:



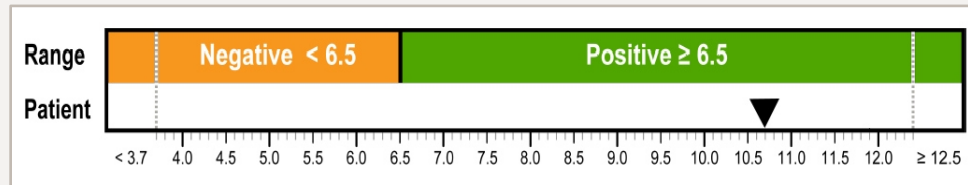
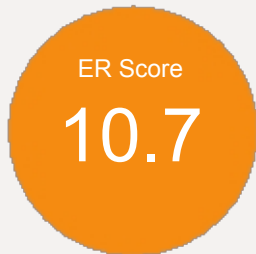
TREATMENT GIVEN

N/A

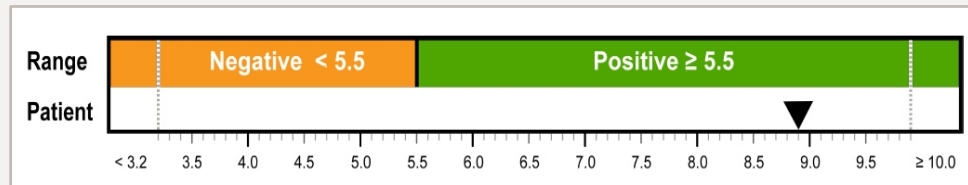
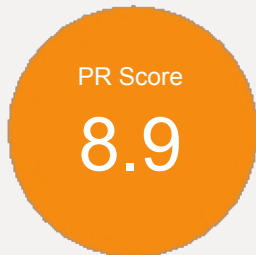DCIS BREAST CASE STUDY

CLINICAL INFORMATION

The Oncotype DX test uses RT-PCR to determine the RNA expression of the genes below. These results may differ from ER or PR results reported using other methods or reported by other laboratories.



N/A



N/A

References

1. Solin et al. J Natl Cancer Inst. 2013.
2. ER Score based on quantitative ESR1 expression (estrogen receptor); PR Score based on quantitative PGR expression (progesterone receptor).
3. Badve et al. J Clin Oncol. 2008. May 20;25(15):2473-81
4. Paik et al. ASCO 2005.