

Colon Case Study

onco*type* DX[®]
Colon Cancer Assay

52-Year-Old Female Patient

Tumor Type: Adenocarcinoma

Tumor Stage: Stage III A/B (N1-3)

Histologic Grade: Low (1)

Lymph Node Status: Negative

Number of Lymph Nodes Assessed: 32

Mismatch Repair (MMR) Status: MMR-P (MSS)

Lymphovascular Invasion: Present

Perforation: Absent

Obstruction: Absent

Other Information: Lymph node status was negative, but extra nodal tumor deposits: N1c
Patient received two does of 5-FU Oxaliplatin, but Oxaliplatin was stopped when the patient showed neuropathy and other signs of intolerable toxicity. The patient is continuing with capecitabine only.

CASE SUBMITTED BY:

Frederick A. Slezak, MD, MBA

Summa Health System

Akron, OH

Colon Case Study

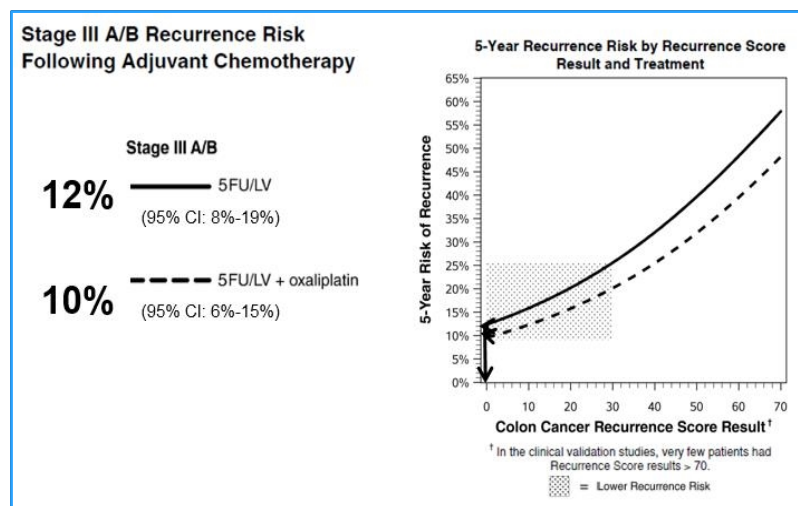
CLINICAL EXPERIENCE

Recurrence Score = **0**

Prognosis for Stage III A/B Colon Cancer Patients Following Adjuvant Chemotherapy

The clinical validation study included patients from the NSAPB C-07 trial which randomized 409 stage III A/B patients to 5FU/LV versus 5FU/LV+oxaliplatin.¹

The average 5 year risk of recurrence for patients who had a Recurrence Score[®] result of 0 was:



Other Considerations: The recurrence risk for patients with ≥ 12 nodes examined was lower than the risk for those with < 12 nodes examined.

References: