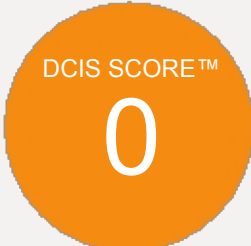

AGE

57

DCIS BREAST CASE STUDY

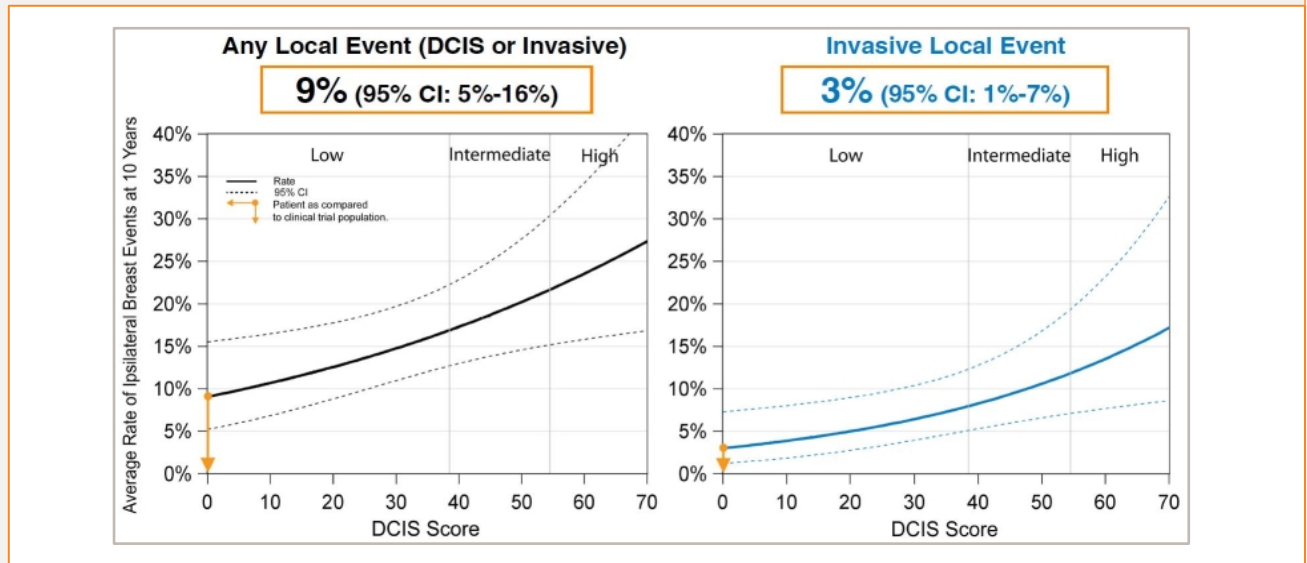
PATIENT	57 Year-Old Female Patient
TUMOR SIZE (cm)	0.9
MENOPAUSAL STATUS	Post-Menopausal
ER STATUS (IHC)	ER positive
MULTIFOCAL	N/A
MARGIN WIDTH (mm)	N/A
NUCLEAR GRADE	N/A
COMEDO NECROSIS	N/A
GENERAL HEALTH	Good
OTHER INFORMATION	Good margins
SUBMITTED BY	George Knaysi, MD and Susan Uhle, NP, Richmond Surgical Center for Breast Care, Richmond, VA



DCIS BREAST CASE STUDY

QUANTITATIVE HORMONE RECEPTOR

The Clinical Validation study¹ included female patients with DCIS treated with local excision without irradiation, and required clear surgical margins ≥ 3 mm and a lesion size of ≤ 2.5 cm. Approximately a third of patients were treated with tamoxifen. The average 10 year rate for ipsilateral breast events for patients who had a DCIS Score of 0 was:

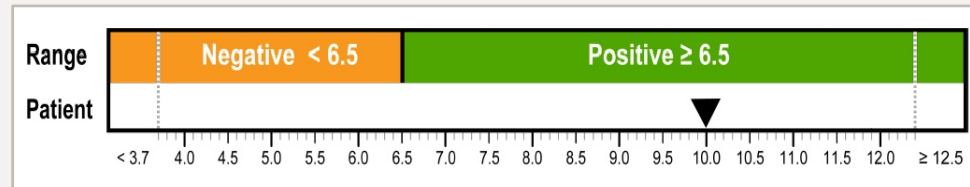
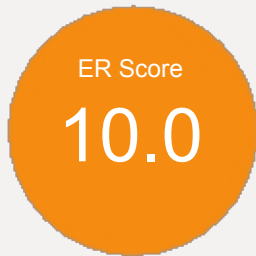

TREATMENT GIVEN	N/A
-----------------	-----

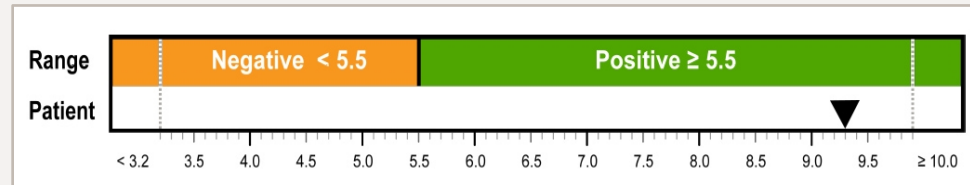
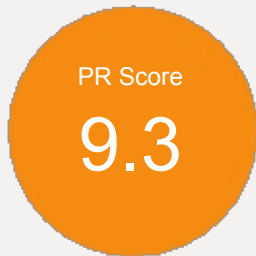DCIS BREAST CASE STUDY

CLINICAL INFORMATION

The Oncotype DX test uses RT-PCR to determine the RNA expression of the genes below. These results may differ from ER or PR results reported using other methods or reported by other laboratories.



N/A



N/A

References

1. Solin et al. J Natl Cancer Inst. 2013.
2. ER Score based on quantitative ESR1 expression (estrogen receptor); PR Score based on quantitative PGR expression (progesterone receptor).
3. Badve et al. J Clin Oncol. 2008. May 20;25(15):2473-81
4. Paik et al. ASCO 2005.