

AGE

43

DCIS BREAST CASE STUDY

PATIENT	43 Year-Old Female Patient
TUMOR SIZE (cm)	0.3
MENOPAUSAL STATUS	Pre-Menopausal
ER STATUS (IHC)	ER positive
MULTIFOCAL	N/A
MARGIN WIDTH (mm)	N/A
NUCLEAR GRADE	2
COMEDO NECROSIS	Present
GENERAL HEALTH	Good
OTHER INFORMATION	N/A
SUBMITTED BY	Linsey Gold, D.O., Michigan Center for Breast Health, Flint, MI

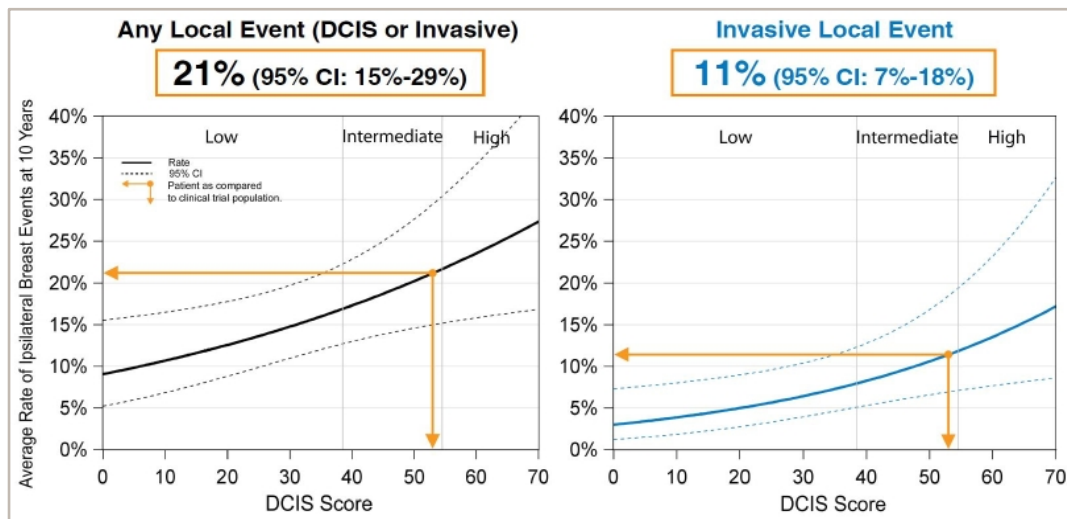
DCIS SCORE™

53

DCIS BREAST CASE STUDY

QUANTITATIVE HORMONE RECEPTOR

The clinical validation study¹ included female patients with DCIS treated with local excision without irradiation, and required clear surgical margins ≥ 3 mm and a lesion size of ≤ 2.5 cm. Approximately a third of patients were treated with tamoxifen. The average 10 year rate for ipsilateral breast events for patients who had a DCIS Score of 53 was:



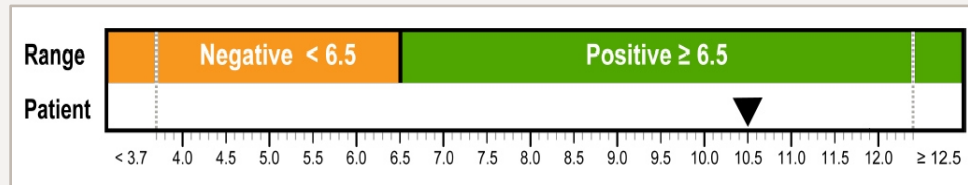
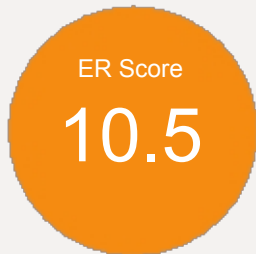
TREATMENT GIVEN

Radiation and hormonal therapy

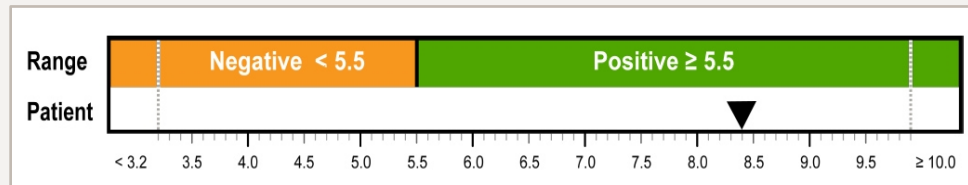
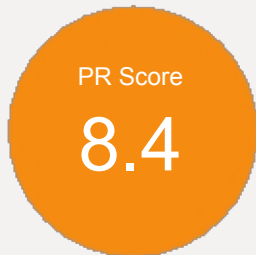DCIS BREAST CASE STUDY

CLINICAL INFORMATION

The Oncotype DX test uses RT-PCR to determine the RNA expression of the genes below. These results may differ from ER or PR results reported using other methods or reported by other laboratories.



N/A



N/A

References

1. Solin et al. J Natl Cancer Inst. 2013.
2. ER Score based on quantitative ESR1 expression (estrogen receptor); PR Score based on quantitative PGR expression (progesterone receptor).
3. Badve et al. J Clin Oncol. 2008. May 20;25(15):2473-81
4. Paik et al. ASCO 2005.