

AGE

55

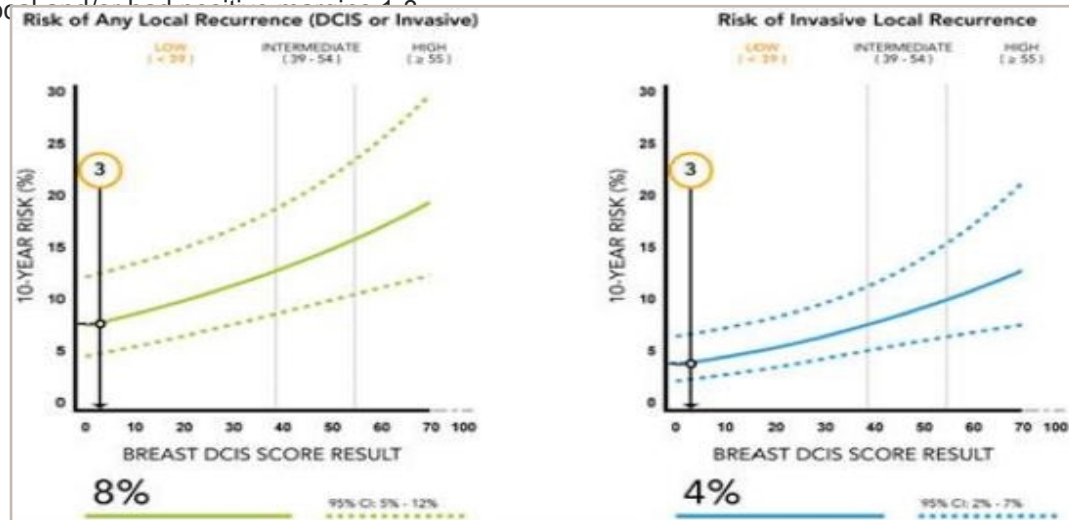
## DCIS BREAST CASE STUDY

PATIENT	55 Year-Old Female Patient
TUMOR SIZE (cm)	1.6
MENOPAUSAL STATUS	Post-Menopausal
ER STATUS (IHC)	ER positive
MULTIFOCAL	N/A
MARGIN WIDTH (mm)	2
NUCLEAR GRADE	2
COMEDO NECROSIS	Absent
GENERAL HEALTH	N/A
OTHER INFORMATION	N/A
SUBMITTED BY	Charles Leonard, MD, Rocky Mountain Cancer Centers, Littleton, CO

# DCIS BREAST CASE STUDY

## QUANTITATIVE HORMONE RECEPTOR

The Breast DCIS Score validation was derived from two studies, E5194 with 327 patients and the Ontario DCIS Cohort Study with 571 patients. The studies consisted of diverse DCIS patient populations treated with breast-conserving surgery alone. The results below reflect a meta-analysis with 773 patients of the two studies incorporating patient age and tumor size with the Breast DCIS Score result to estimate 10-year risk. The meta-analysis excluded patients whose tumors were multifocal.



TREATMENT GIVEN	N/A
-----------------	-----

# DCIS BREAST CASE STUDY

## CLINICAL INFORMATION

The Oncotype DX test uses RT-PCR to determine the RNA expression of the genes below. These results may differ from ER or PR results reported using other methods or reported by other laboratories.

ER Score

N/A



N/A

PR Score

N/A



N/A

### References

1. Solin et al. J Natl Cancer Inst. 2013.
2. ER Score based on quantitative ESR1 expression (estrogen receptor); PR Score based on quantitative PGR expression (progesterone receptor).
3. Badve et al. J Clin Oncol. 2008. May 20;25(15):2473-81
4. Paik et al. ASCO 2005.